



http://app.pan.pl/SOM/app66-Benoit2_etal_SOM.pdf

SUPPLEMENTARY ONLINE MATERIAL FOR

Can maxillary canal morphology inform varanopid phylogenetic affinities?

Benoit, J., Ford, D.P., Miyamae, J.A., and Ruf, I.

Published in *Acta Palaeontologica Polonica* 2021 66 (X): xxx-xxx.

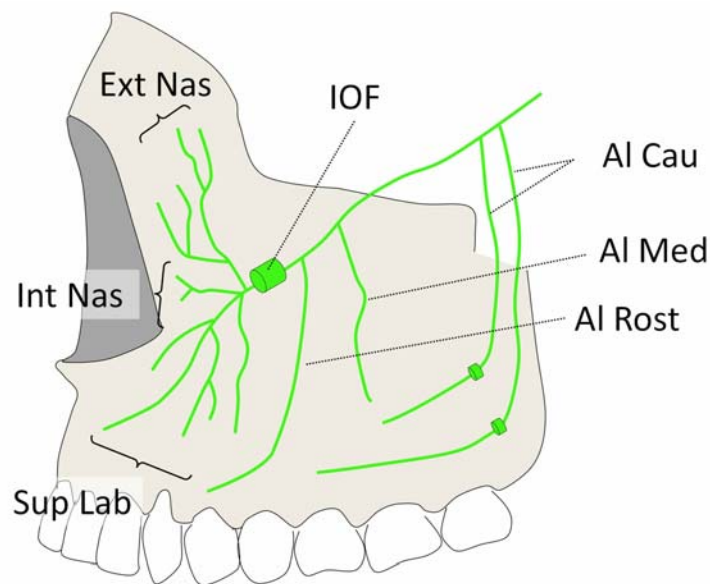
<https://doi.org/10.4202/app.00816.2020>

Supplementary Online Material

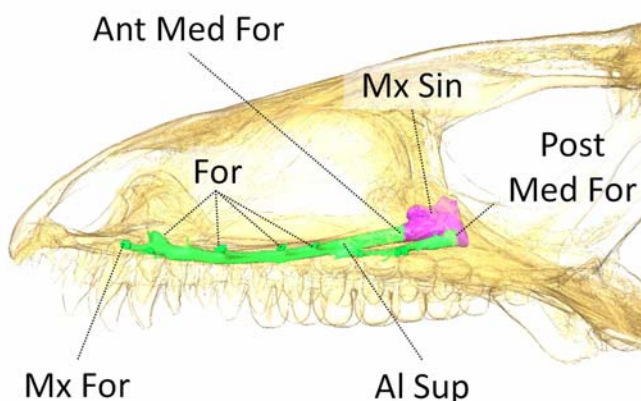
Fig. S1. Lateral view of the maxillary nerve in a mammal, and the maxillary canal in a reptile and non-mammalian therapsid.

Fig. S1. Lateral view of the maxillary nerve in a mammal (A), and the maxillary canal in a reptile (B) and non-mammalian therapsid (C) (after Benoit et al. 2016a). A, modern *Homo sapiens* (Lineaus, 1758); B, modern *Varanus* sp. (Linnaeus, 1766); C, *Olivierosuchus parringtoni*, Brink, 1965 (BPI/1/3849), from the early Triassic of the New Castle of the Admiralty Estates (Bergville District, South Africa). Abbreviations: Al Cau, caudal alveolar nerve (or canal); Al Med, medial alveolar nerve (or canal); Al Ros, rostral alveolar nerve (or canal); Al Sup, superior alveolar nerve (or canal); Ant Med For, anterior medial foramen for the superior alveolar nerve; Ext Nas, external nasal nerve (or canal); Int Nas, internal nasal nerve (or canal); Mx For, anterior maxillary foramen; Mx Sin, maxillary sinus; Sup Lab, superior labial nerve (or canal); Post Med For, posterior medial foramen for the infraorbital artery (maxillary artery).

A. Mammalia



B. Reptilia



C. Therapsida

